

Pulmonary Papillomatosis: HPV-11 Mutation & Vorinostat Therapy

Jennifer Woo MS¹; Hang Yuan PhD¹; Xuefeng Liu PhD¹; Richard Schlegel MD, PhD¹; Nazaneen Grant MD²; Earl Harley MD²; Scott Myers MD³

¹Department of Pathology; ²Department of Otolaryngology; ³Department of Pediatric Oncology
Georgetown University School of Medicine – MedStar Georgetown University Hospital, Washington DC

OBJECTIVES

- Report isolation of HPV-11 with viral genome duplication in the lung tumor lesions of a 23-year-old male with a 20-year history of recurrent respiratory papillomatosis;
- Describe pulmonary RRP response to vorinostat therapy, following previous disease progression resistant to alpha-interferon, intralesional cidofovir, intralesional bevacizumab, and oral methotrexate.

ABSTRACT

A patient with a 20-year history of recurrent respiratory papillomatosis (RRP) presented with progressive, bilateral tumor invasion of the lung parenchyma. Cell cultures were generated from the patient's normal and tumor tissue using conditional reprogramming techniques. DNA extracted from cultured tumor cells was subjected to PCR analysis, which revealed a 10.4 kb mutant HPV-11 genome in the lung tumor cells. Chemosensitivity screening identified vorinostat as a potential therapeutic, and treatment was initiated. The patient demonstrated stabilization of tumor growth after 3 months of treatment, with durable effects for 15 months.

BACKGROUND

Recurrent respiratory papillomatosis (RRP) is a benign neoplasm of the upper aerodigestive tract. Most cases are diagnosed in childhood, and are caused by infection with human papillomavirus type 6 or 11 (HPV-6, -11), acquired at birth. HPV-11 is associated with a more aggressive clinical course, including lung involvement¹. Standard treatment of RRP is repeated surgical debulking of tumors using laser or microdebrider. Rarely, RRP can extend distally beyond the larynx to the trachea, mainstem bronchi, and lung. There is currently no effective therapy for pulmonary involvement of RRP, and prognosis is always serious². Furthermore, the absence of an effective cell culture method for HPV genome analysis in the respiratory epithelium has long impeded the progress of RRP research and the availability of chemosensitivity screening of RRP tumors.

CASE PRESENTATION

Our patient is a 23-year-old African American male who has undergone over 350 laser procedures to treat his laryngeal and pulmonary papillomas, including tracheostomy and multiple thoracotomies. Previously, he received treatment with interferon (1996-2010), methotrexate (2001-2003), intralesional cidofovir (2007-2010), and intralesional bevacizumab (2010). In 2010, CT scans revealed multiple pulmonary nodules accelerating in growth, with 3 index tumors increasing in size by 21%, 72%, and 130% in 11 months. The patient is classified clinically as having chemo-resistant, progressive disease.

METHODS

•Procurement, isolation, and amplification of DNA

Following right upper lobe segmentectomy and laser ablation of laryngeal papilloma, samples of the patient's tumor tissue were collected with informed consent according to Georgetown University Hospital IRB protocol. Tumor cells were cultured using a novel conditional reprogramming system, and DNA from both laryngeal and pulmonary tumor cells was isolated, amplified, and subjected to PCR analysis using HPV-11 primers to the L1 gene or the junction of the E1(A) and L1(B) regions.

•Chemosensitivity screening of tumor cells

Lung tumor cells were isolated, plated with feeder cells, and treated with vehicle (DMSO), cidofovir, dihydroartemisinin (DHA), or vorinostat dissolved in DMSO. Cell viability was measured after 48 hours of incubation.

•Vorinostat treatment protocol

Based on the results of the chemosensitivity screening, treatment with vorinostat (a histone deacetylase inhibitor used to treat cutaneous lymphoma) was initiated at 400 mg daily on a 4 week cycle (3 weeks on, 1 week off). This protocol was continued for one year.

RESULTS

•PCR detection of HPV-11 mutation in lung tumor cells only

PCR analysis of DNA extracted from laryngeal and lung tumor cells identified a 2kb duplication of the HPV-11 genome in the lung lesions only, including a novel duplication of the upstream promoter and the E6/E7 oncogenes. This mutation was not detected in laryngeal tumor cells.

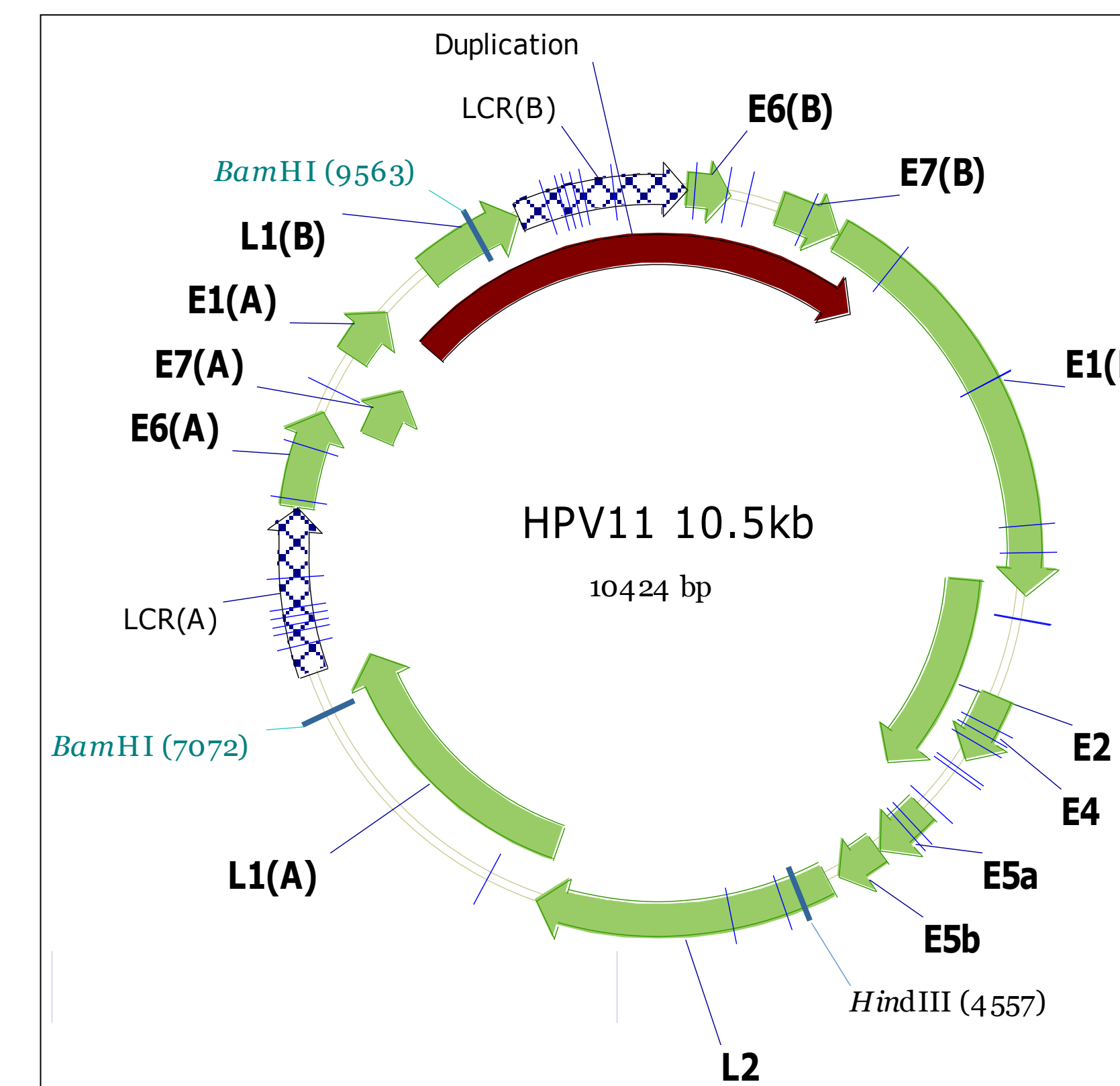
•Chemosensitivity assay suggests vorinostat as potential therapeutic

The most effective drug against cultured tumor cells was vorinostat, lethal to the tumor cells at 1-2 uM concentrations. Cidofovir, which was demonstrated earlier to be clinically ineffective in this patient, was completely ineffective in vitro even at very high concentrations (50-200 uM).

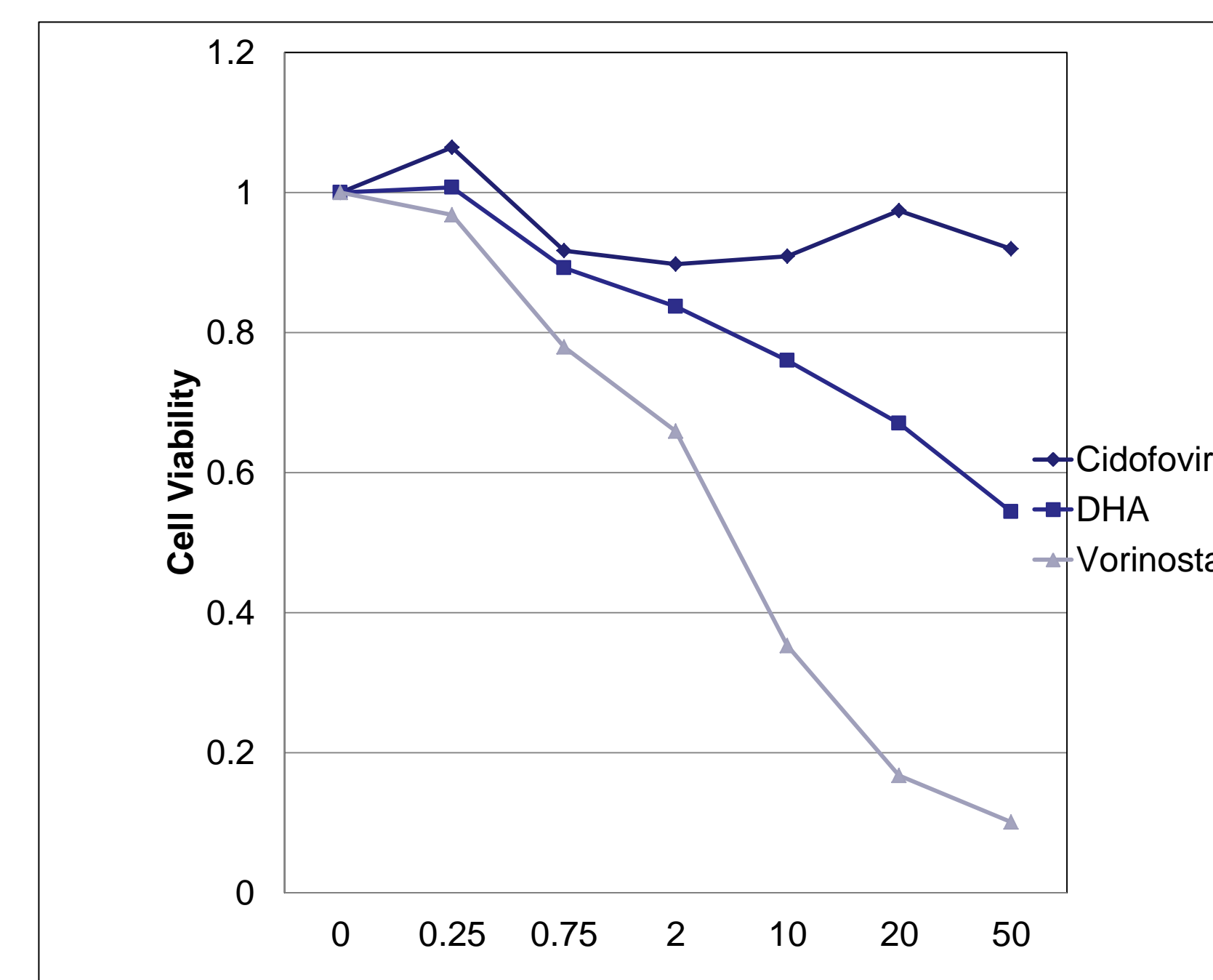
•Vorinostat therapy induces tumor regression and stabilization

After 3 months of treatment with vorinostat, CT scans showed regression of existing pulmonary tumors, with no new lesions identified. A lesion in the right lower lobe demonstrated a measurable decrease between January and April 2011. Two lung tumors and 1 hilar lymph node, considered "measurable target lesions" in January 2011 per Response Evaluation Criteria in Solid Tumors (RECIST), decreased 16% from baseline after 3 months of vorinostat treatment. Throughout and following 12 months of treatment, tumor sizes in the lungs have remained stable, with most recent measurements taken in April 2012. The patient tolerated the therapy well, with only mild toxicity (increased Cr/blood pressure, occasional abdominal cramps, alopecia). The severity of the patient's laryngeal disease, measured by frequency of visits to the OR for laser ablation per the patient's subjective symptoms, remains unchanged.

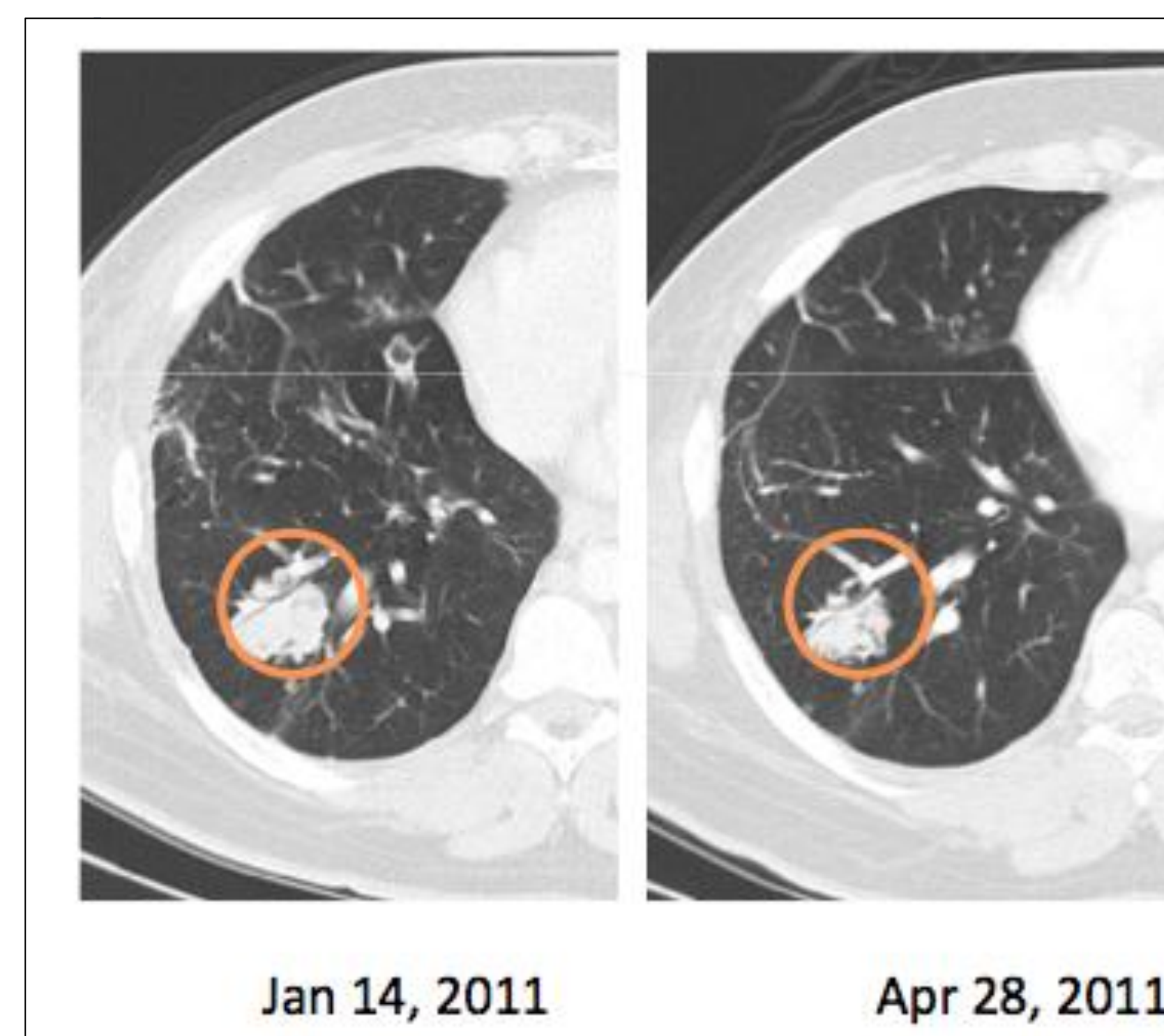
FIGURES



A. Map of the 10.5 kb mutant HPV-11 genome isolated from lung tumor cells only, including a 2kb duplication of the L1 promoter region and E6/E7 oncogenes.



B. Pulmonary tumor cells were more sensitive to vorinostat compared to DHA and cidofovir following 48-hr incubation.



C. Interval CT after 3 months of vorinostat demonstrated reduction in right lower lobe tumor size.

DISCUSSION

The burden of morbidity in RRP is extremely high, as is mortality associated with extension of laryngeal papillomas into the lungs. The precise pathogenesis of pulmonary involvement remains unclear, though clinically aggressive disease in the distal airways appears to be associated with HPV-11 infection³ or with history of tracheostomy causing mechanical disruption of the respiratory mucosa.

Advancements in RRP research have been impeded by the absence of effective methods for culturing tumor cells for genome analysis and chemosensitivity screening. Using a novel method to generate conditionally reprogrammed cells, we were able to establish a long-term culture of RRP tumor cells, from which DNA was isolated and analyzed to detect a 2kb mutation of the HPV-11 L1 promoter region and E6/E7 oncogenes unique to the lung tumor cells. The role of the E6 and E7 in the immortalization, transformation, and carcinogenesis of "high risk" HPV types has been well established. We believe this mutation contributes to the clinically aggressive phenotype of this patient's disease, and that detection of intragenomic duplication in RRP viral genomes may predict poor clinical outcome.

Advancements in pulmonary RRP treatment have been stymied by the challenge of drug delivery to lung tumors, and by the limited resectability of diseased parenchyma. We present the first documented use of chemosensitivity screening to identify candidate medical therapies for pulmonary RRP. Vorinostat, which has been used cutaneous lymphoma⁴, recurrent glioblastoma multiforme, and advanced non small cell lung cancer, has also demonstrated some effectiveness against HPV-16 cell lines⁵. Vorinostat has stabilized this patient's disease over a 15-month period. Further studies are warranted to determine whether this therapeutic approach may be generalized to other cases of pulmonary RRP.

CONCLUSION

- Mutation of the HPV-11 L1 promoter and E6/E7 oncogenes in this patient's pulmonary tumors may contribute to the clinical aggressiveness of his disease.
- Chemosensitivity screening identified vorinostat as a candidate therapy that has stabilized this patient's pulmonary disease after a 12-month course of treatment.

References

1. Derkay CS, Wiatrak B. Recurrent respiratory papillomatosis: a review. *Laryngoscope* 2008; 118(7):1236-47.
2. Goon P, Sonnex C, Jani P, Stanley M, Sudhoff H. Recurrent respiratory papillomatosis: an overview of current thinking and treatment. *Eur Arch Otorhinolaryngol* 2008; 265(2): 7-14.
3. Cook JR, Hill DA, Humphrey PA, Pfeiffer JD, El-Mohy SK. Squamous cell carcinoma arising in recurrent respiratory papillomatosis with pulmonary involvement: emerging common pattern of clinical features and human papillomavirus serotype association. *Mod Pathol* 2000; 13(8): 914-8.
4. Duvic M, Talpur R, Ni X, et al. Phase 2 trial of oral vorinostat (suberoylanilide hydroxamic acid, SAHA) for refractory cutaneous T-cell lymphoma (CTCL). *Blood* 2007; 109(1):31-9.
5. Diatrow GL, Baegle AC, Kierpicek KA, et al. Dihydroartemisinin is cytotoxic to papillomavirus-expressing epithelial cells in vitro and in vivo. *Cancer Research* 2005; 65(23): 10854-61.