



Flexible CO2 laser in the Head and Neck: Single institution outcomes for first 4 years

A. Lambert, C. Giddings, F. Vaz, P. O'Flynn

Head & Neck Unit, University College London Hospital, London, UK



Introduction

Patients who present with difficult to access lesions in the upper aerodigestive tract during diagnostic and therapeutic procedures pose a challenge. Conventional methods of straight-line CO2 laser may not enable some lesions to be treated via an endoscopic/closed surgical approach. Flexible CO2 laser technology increases the surgical options for these patients.

Objectives

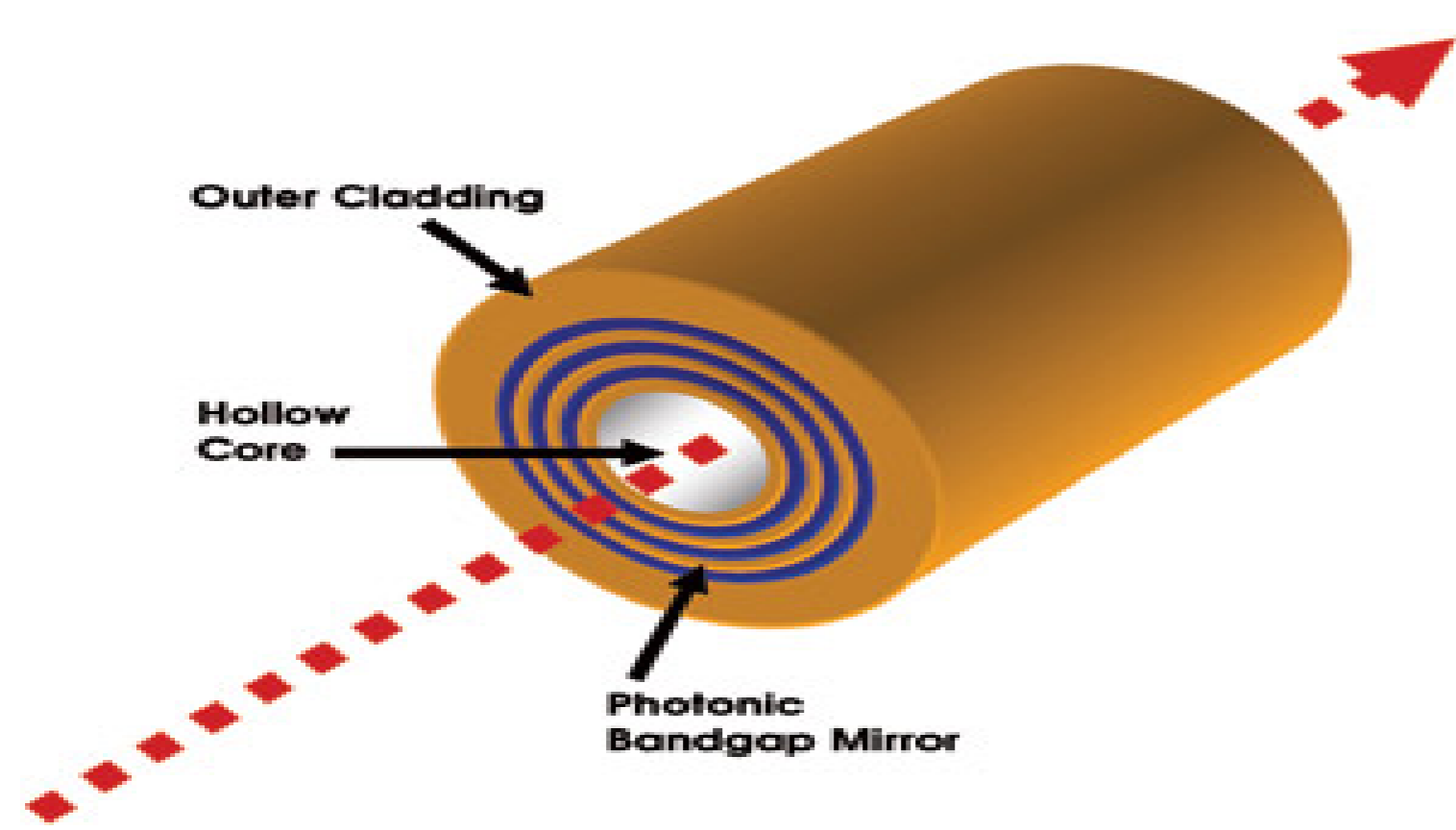
Determine the surgical, oncological and functional outcomes of patients treated with the flexible CO2 laser for head and neck lesions without robotic assistance.

Materials and methods

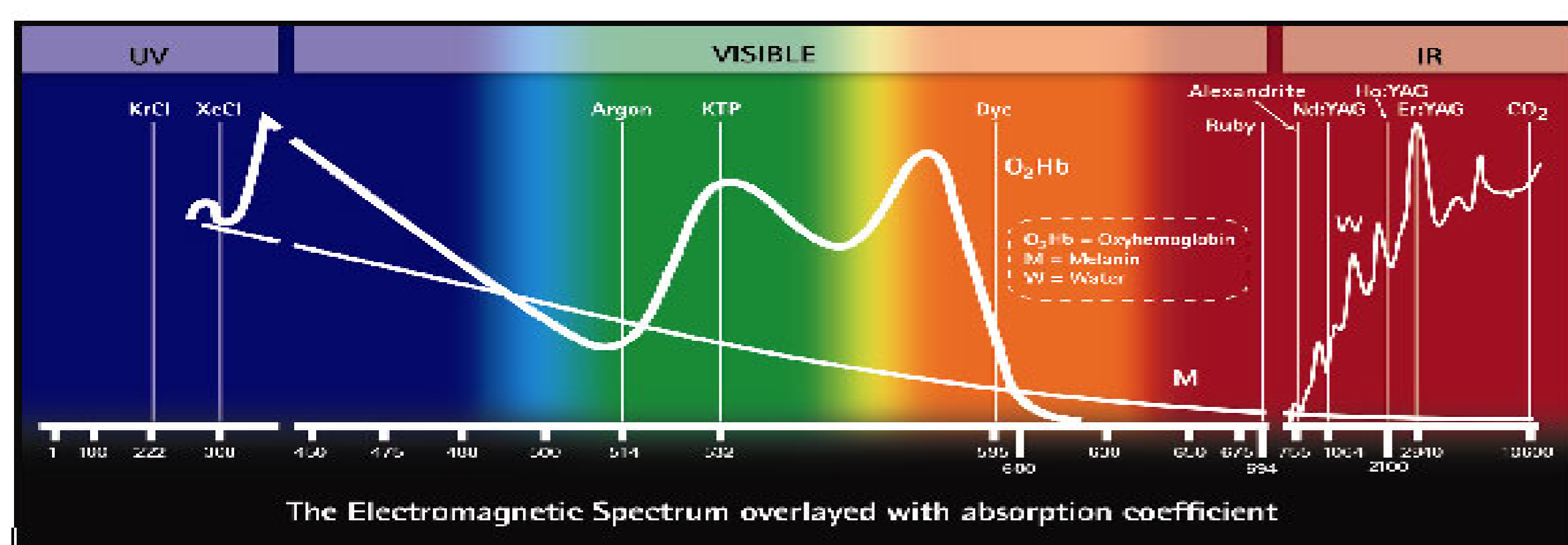
Retrospective case review of patients treated with the Omniguide® Flexible CO2 laser (Cambridge, MA, USA) in the Head and Neck unit of a university teaching hospital.

Background to Omniguide® Flexible CO2 Laser

In the 1990's the dependence on existing line-of-sight CO2 lasers was overcome by using a hollow fibre made of a novel omnidirectional dielectric mirror.

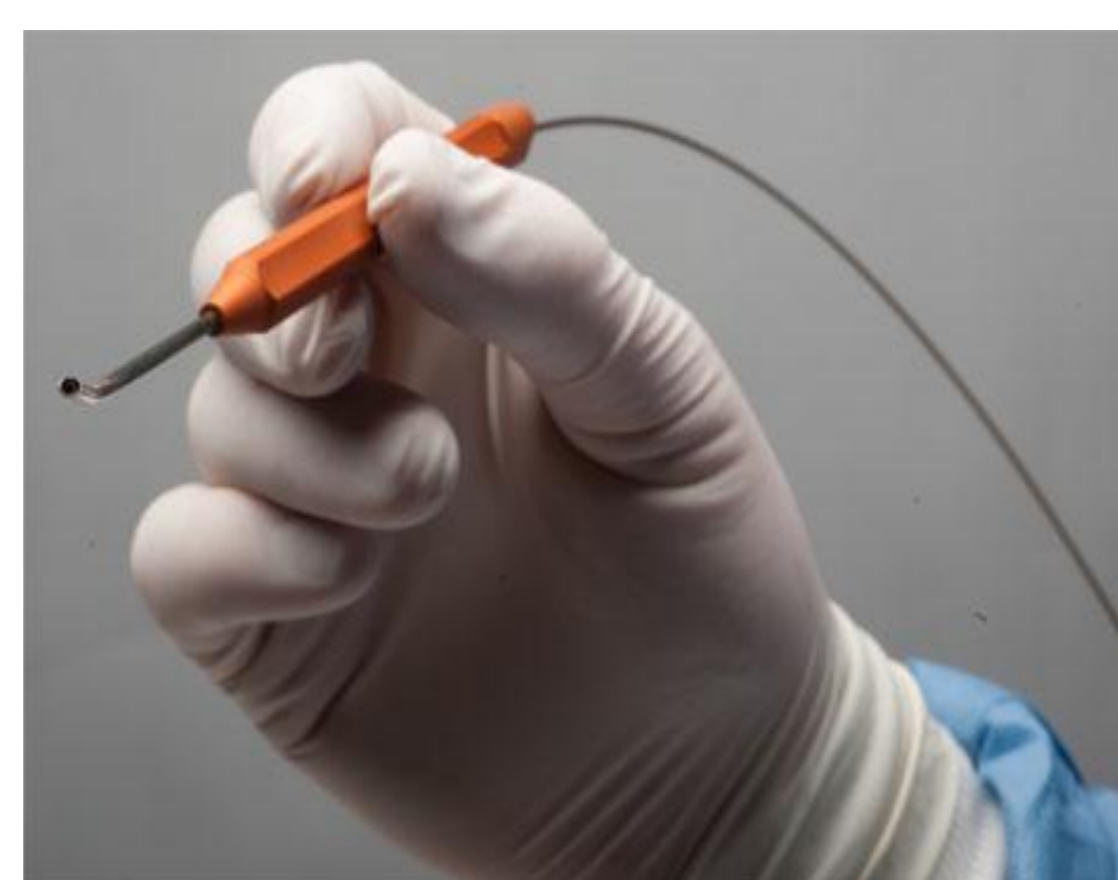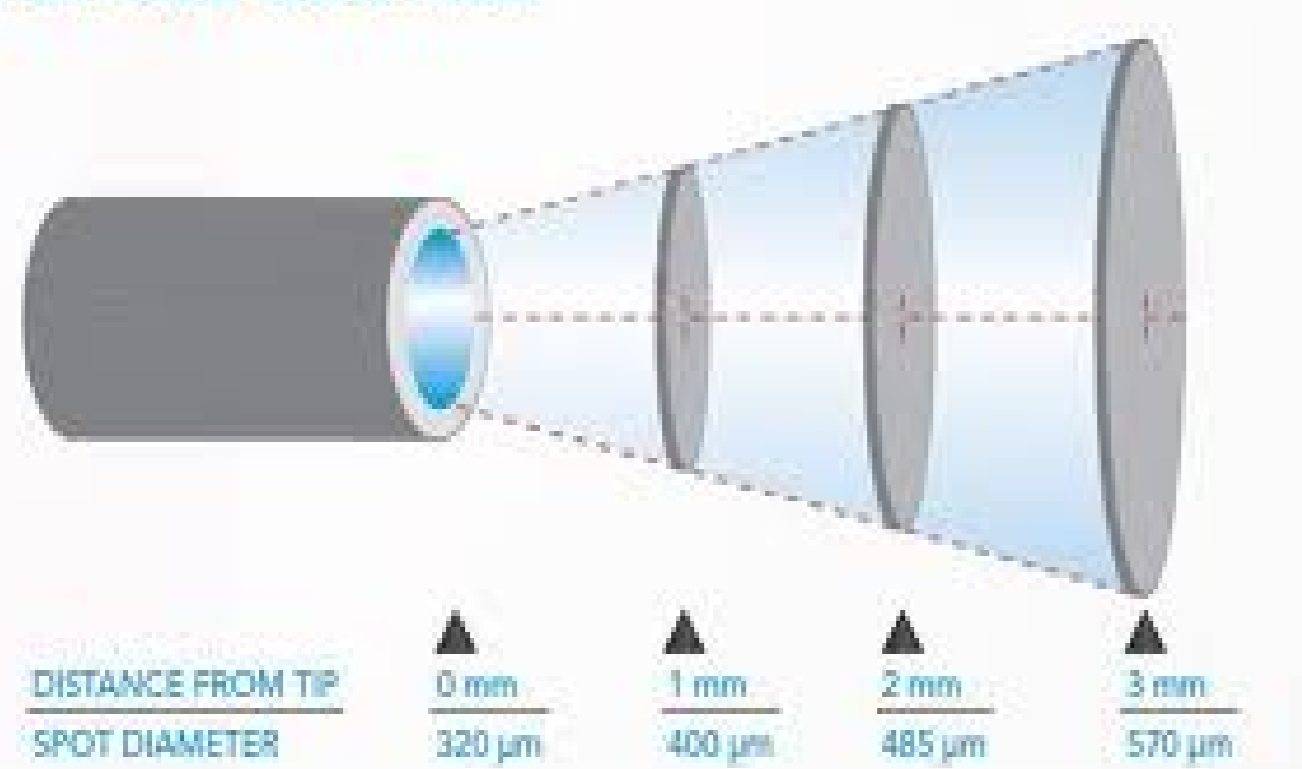


This allowed the CO2 laser beam to turn corners for the first time. CO2 has advantages over other flexible lasers (Thulium, Pulse-Dye-Laser and KTP) because its wavelength permits excellent haemostasis and sub-millimetre cutting precision with minimal surrounding thermal damage.



The Omniguide Flexible CO2 laser fibre is normally used with specially designed hand-pieces, but can also be used via an endoscope (e.g. bronchoscope) instrument channel. Spot-size is controlled by varying the distance from the tissue target. Helium is used in the core of the hollow fibre to cool the fibre and expel debris from the fibre-tip.

SPOT SIZE CONTROL



Results

21 patients underwent 24 procedures from January 2009 to January 2013.

15 procedures involved confirmed invasive carcinoma (T1 to T3). 5 patients underwent further surgery due to involved margins/early local recurrence.

6 month disease free survival of patients with confirmed cancer was 77%.

Other pathology included squamous papilloma (2), lymphoid hyperplasia (3), vascular lesions (2), and severe dysplasia (2). Anatomic subsites of all cases are listed below.

Complications

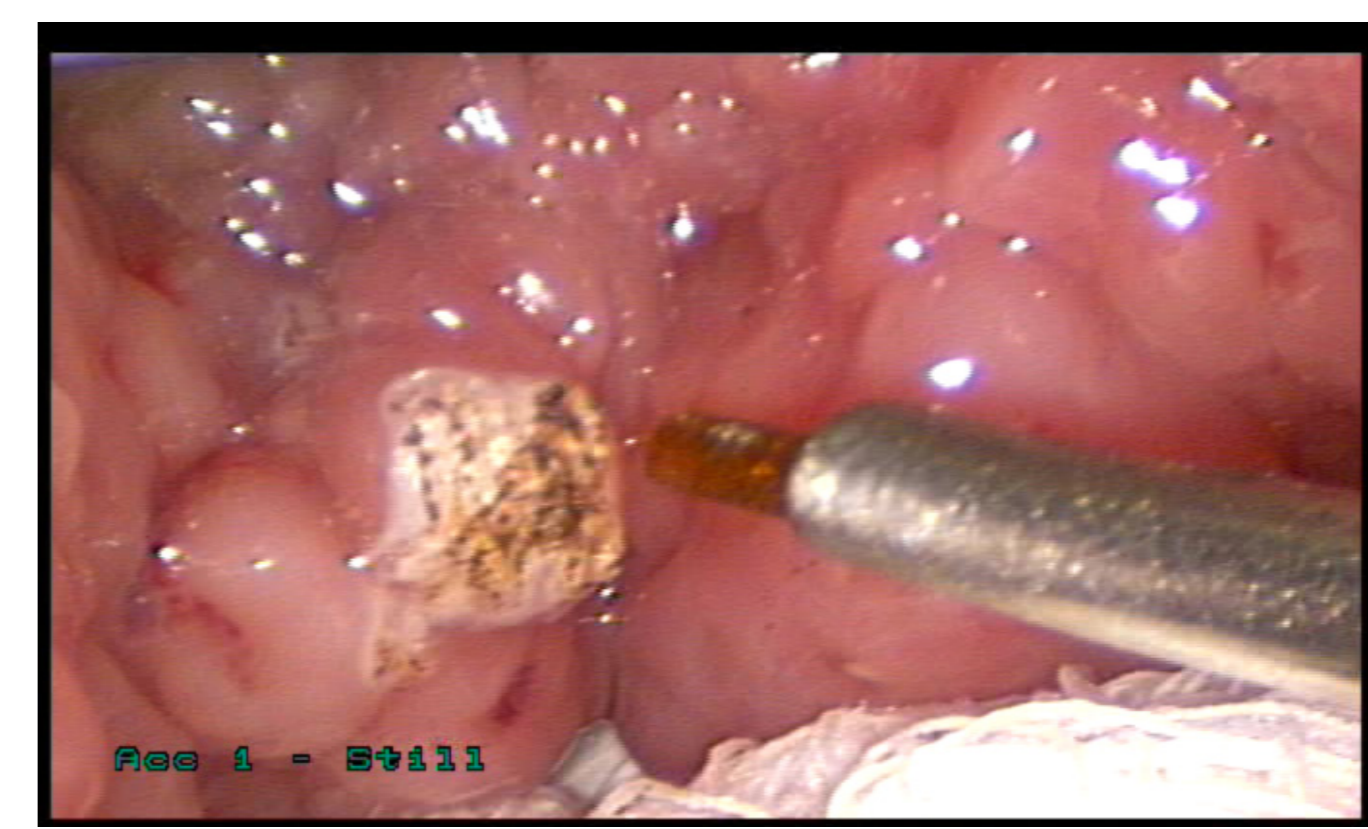
One case required semi-elective intraoperative tracheostomy, nasogastric tube, and a 21 day length of stay.

All other patients returned to oral intake prior to discharge.

No other airway complications were reported.

In no cases was there a failure to proceed with surgery.

Mean length of stay 1.5 days. Range 1-21 days



Anatomic Subsites included in case series

| | |
|---------------------------|----|
| Larynx | 15 |
| -Glottis | 6 |
| -Supraglottis | 3 |
| -Subglottis/Upper trachea | 6 |
| Base of tongue/tongue | 8 |
| Nasopharynx | 1 |
| TOTAL | 24 |

Conclusions

Our experience of using a CO2 photonic bandgap laser fibre in Head and Neck disease without robotic assistance provides the first published oncological and functional outcome data for this modality.

Our data is representative of the diverse cases selected for this technique in our unit. Our 3 cases of T3 squamous cell carcinoma represent patients who declined laryngectomy. All other patients had anatomy which precluded accessing the lesions with a straight-line CO2 laser.

The cost per case is a significant factor (approximately GBP£500), but may be offset by reduced length of stay and improved morbidity compared with open resection.

The authors have no financial disclosures/competing interests to declare.

References

1. Abraham R.F., L'Official J., Shapshay S.M. Use of a flexible CO2 laser fiber delivery system in otolaryngology head and neck surgery: Multi-institutional experience. *Laryngoscope*. 119 (SUPPL.3) (pp S213), 2009.
2. Remacle M, Ricci-Maccarini A, Matar N, Lawson G, Pieri F, Bachy V, Nollevaux MC. Reliability and efficacy of a new CO2 laser hollow fiber: a prospective study of 39 patients. *Eur Arch Otorhinolaryngol*. 2012 Mar;269(3):917-21
3. O'Flynn P, Awad Z, Kothari P, Vaz FM. The first UK report of the applications of flexible CO laser in head and neck surgery: how we do it. *Clin Otolaryngol*. 2010 Apr;35(2):139-42