

# Classification System for Lateral Pharyngotomy

Courtney B. Shires, MD<sup>1</sup>; David W. Rodwell, MD<sup>1</sup>; Chafeek Tomeh, MD<sup>1</sup>; Merry E. Sebelik, MD<sup>1</sup>; Sandeep Samant, MD<sup>1</sup>

<sup>1</sup>University of Tennessee Health Science Center, Department of Otolaryngology

## ABSTRACT

**Objectives:** 1. Propose a classification system of lateral pharyngotomy (LP) used in exposing various sites of the oropharynx, supraglottis, and hypopharynx. 2. Describe the structures visible with each category of lateral pharyngotomy.

**Study Design:** Anatomic study

**Setting:** Medical Education and Research Institute, Memphis, TN.

**Subjects:** 5 fresh-frozen human cadavers

**Methods:** After exposure of the neurovascular structures of the anterior compartment of the neck and laryngeal framework, pharyngotomy was performed with entry between the hypoglossal nerve cephalically and the superior laryngeal nerve caudally (Type I LP). Exposure caudally toward the pyriform apex was provided by dividing the superior laryngeal artery (Type II LP). To create wider exposure in the anterior direction, the digastric and stylohyoid muscles were transected (Type III LP). Division of the hyoglossus and mylohyoid muscles resulted in Type IV LP. The ability to visualize certain structures (epiglottis, ipsilateral and contralateral base of tongue, postcricoid area, arytenoids, uvula, soft palate, and vallecula) through the pharyngotomy was recorded.

**Results:** The epiglottis and ipsilateral tongue base were visible in Type I LP. Type II LP provided exposure of the postcricoid area, arytenoids, and cervical esophageal inlet. Type III LP provided exposure of the entire base of tongue, uvula, and soft palate, while Type IV LP added visualization of the vallecula and contralateral tonsil.

**Conclusion:** Caudal exposure is augmented in type II pharyngotomy; increasing cephalic exposure is facilitated in types III and IV. This anatomic study illustrates the structures requiring division to provide access to a given tumor location.

## CONTACT

Courtney Shires, MD  
University of Tennessee Health Science Center  
Email: cshires1@gmail.com  
Phone: 901-448-5886

## INTRODUCTION

Originally described in 1878 by Cheever, the lateral pharyngotomy approach has been used to access benign and malignant tumors of the tonsil, base of tongue, epiglottis, oropharyngeal wall, soft palate, and supraglottis but is most useful for tumors of the posterior pharyngeal wall and small tumors (T1 or T2) of the base of tongue.<sup>1,2,3</sup> Surgeons may find it difficult to visualize the entire tumor using the traditional window for pharyngotomy between the hypoglossal nerve superiorly and the superior laryngeal nerve inferiorly. Therefore, maneuvers to provide wider exposure have been described, including transecting the superior laryngeal nerve; removing the lateral third of the hyoid bone or the superior cornu of the thyroid cartilage; transecting the thyrohyoid ligament; dividing the digastric, stylohyoid, hyoglossus, or mylohyoid muscles; ligating the external carotid artery; or performing lateral mandibular osteotomy.<sup>3</sup> However, there is no systematic classification of these maneuvers. We, therefore, describe a new system of dividing additional structures to provide better access and visualization.

## METHODS AND MATERIALS

Permission for use of cadavers for academic study was granted by the Medical Education and Research Institute in Memphis, Tennessee. Five fresh-frozen cadavers were obtained from the laboratory for dissection. None of the cadavers had a history of benign or malignant lesions of the oropharynx, larynx, or hypopharynx. None had a history of neck surgery. No cutaneous scars of the neck were noted. Lateral pharyngotomy was performed as described by Ferris and Meyers and labeled Type I LP.<sup>4</sup> Three other maneuvers were then systematically performed to provide greater access. These were labeled Type II, III, and IV LP and are described below. A zero degree endoscope was placed into the pharynx to visualize the pharyngotomy incisions transorally as they were performed transcervically.

**Type I pharyngotomy.** A low horizontal incision along a skin crease of the neck was performed. Subplatysmal flaps were raised superiorly and inferiorly. Blunt dissection was performed along the anterior border of the sternocleidomastoid muscle to separate this muscle from the strap muscles. The carotid sheath and its contents were visualized. The hypoglossal nerve was skeletonized along its length, which allowed cephalic retraction of the nerve. The inferior constrictor muscle, superior pole of the thyroid gland, and superior thyroid vascular pedicle were visualized. The superior laryngeal nerve, in its inferomedial course, was exposed by retracting the external carotid artery. Superiorly, the hypoglossal nerve was seen coursing anteriorly between the internal carotid artery and internal jugular vein. The window for pharyngotomy was bordered superiorly by the hypoglossal nerve and inferiorly by the superior laryngeal nerve. The inferior constrictor muscle was then transected over the posterior edge of the thyroid ala. The pyriform sinus mucosa was opened. The ability to visualize certain structures (epiglottis, ipsilateral and contralateral base of tongue, postcricoid area, arytenoids, uvula, soft palate, and vallecula) through the pharyngotomy was recorded.

**Type II pharyngotomy.** Type I pharyngotomy was performed as described above. Division of the superior laryngeal artery was performed. The length of additional exposure inferior to the superior laryngeal nerve to the upper border of the thyroid ala was recorded. The anatomic landmarks visualized were recorded.

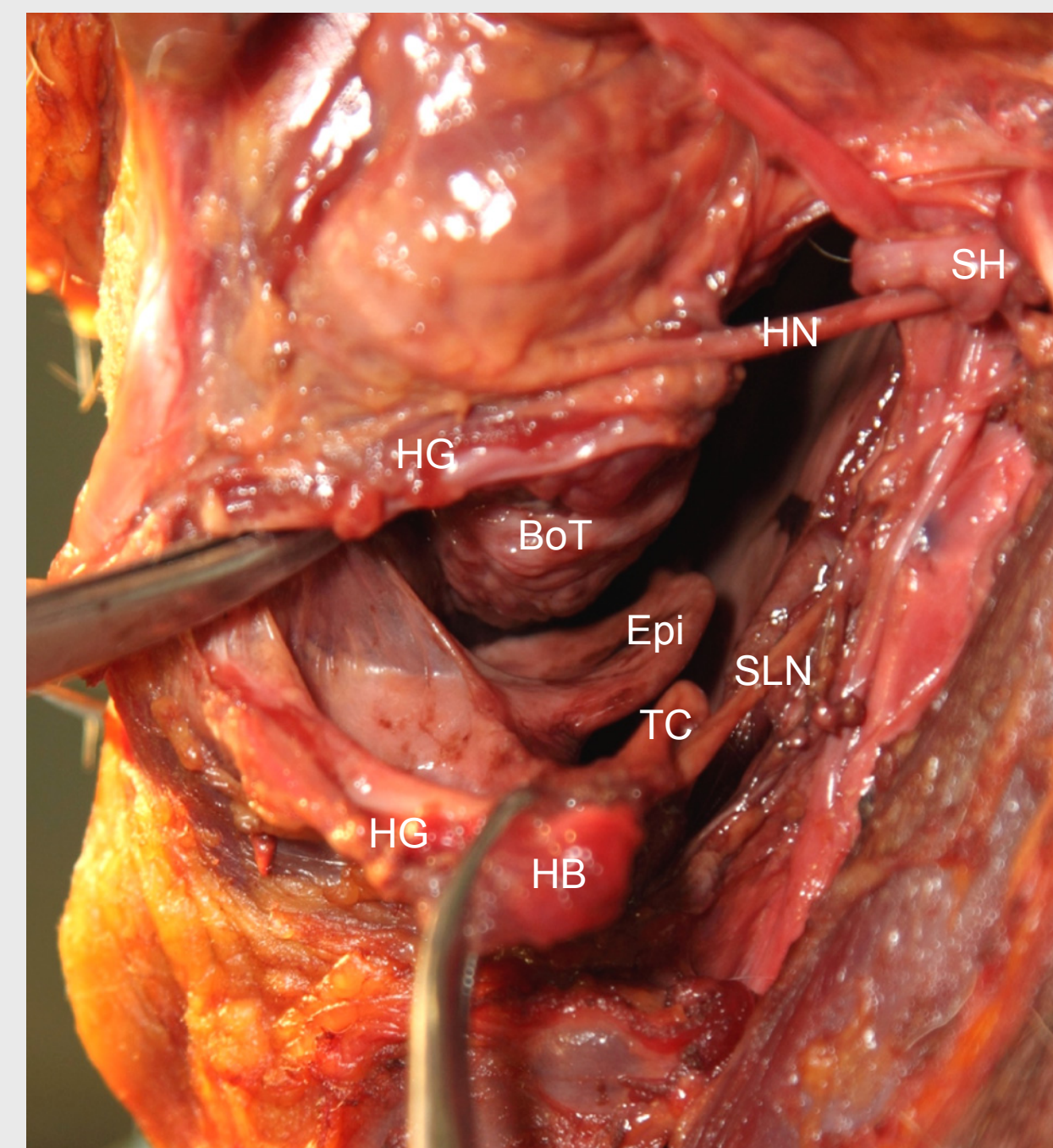
**Type III pharyngotomy.** Type I and II pharyngotomies were performed. In addition, the digastric and stylohyoid muscles were divided (Figures 1 and 2). The length of additional exposure through the pharyngotomy as well as the visualized anatomic landmarks were recorded.

**Type IV pharyngotomy.** Type I, II, and III pharyngotomies were performed. In addition, the mylohyoid and hyoglossus muscles were divided. The length of additional exposure through the pharyngotomy as well as the visualized anatomic landmarks were recorded.

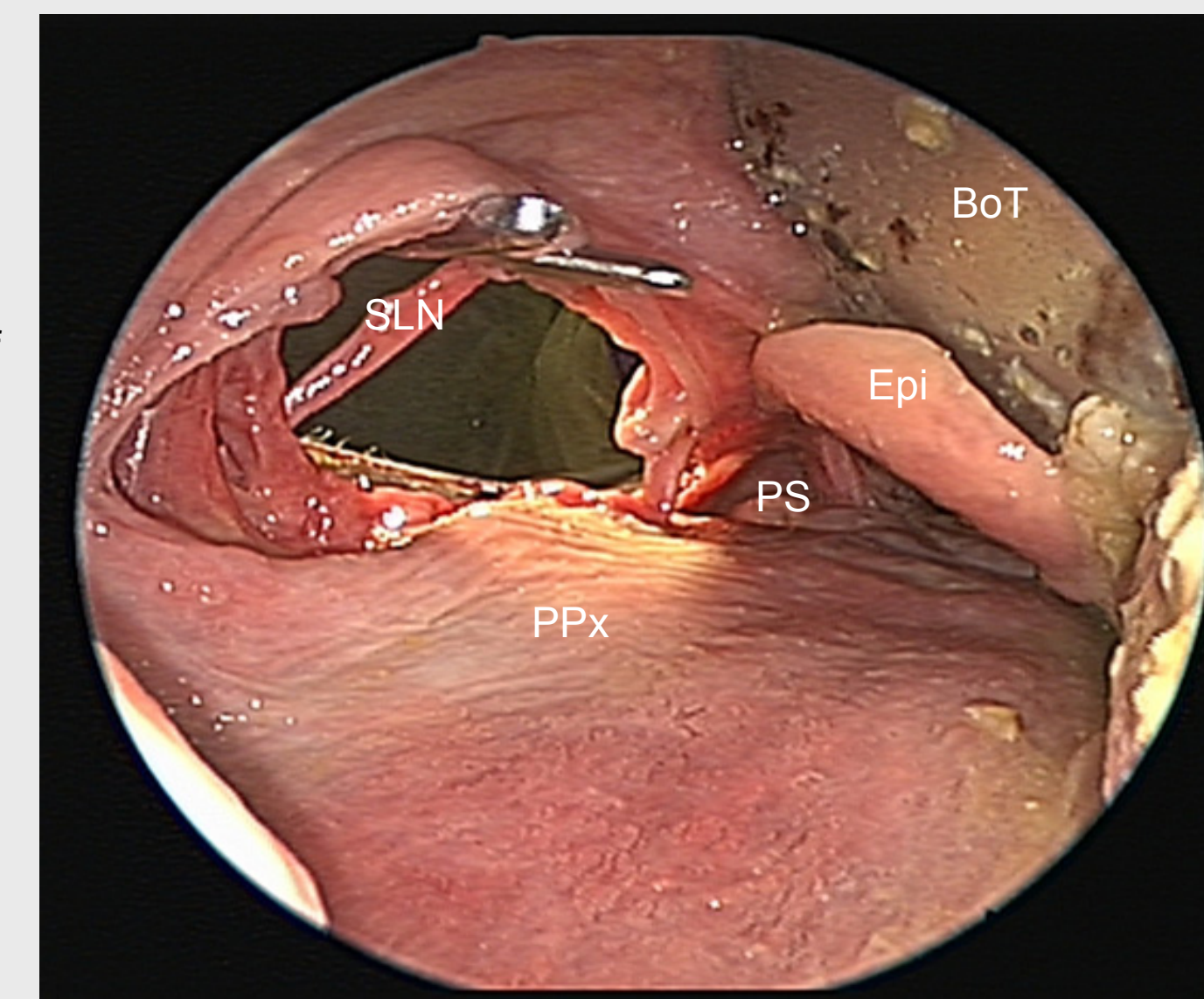
## RESULTS

After performing Type I LP, the epiglottis and ipsilateral base of tongue were visualized in all specimens. With the addition of Type II LP, the postcricoid area and arytenoids were also visible. Type III LP allowed visualization of all the base of tongue, the uvula, and the soft palate. Type IV LP provided additional visualization of the vallecula in 2 of the 5 cadavers.

Visualization of the mucosal incisions using a transoral zero degree endoscope was possible in all cadavers.



**Figure 1.** Type III lateral pharyngotomy, left side. SH- reflected stylohyoid muscle, HG- cut edges hyoglossus muscle, HN- hypoglossal nerve, HB- hyoid bone, in retractor, BoT- base of tongue, Epi- epiglottis, SLN- superior laryngeal nerve, TC- superior horn of thyroid cartilage.



**Figure 2.** Transoral endoscopic view of type III lateral pharyngotomy, left side. SLN- superior laryngeal nerve, PPx- posterior pharyngeal wall, PS- pyriform sinus, Epi- epiglottis, BoT- base of tongue.

## DISCUSSION

Several approaches including suprahyoid, transhyoid, and subhyoid pharyngotomy; lateral pharyngotomy; mandibulotomy; and transoral laser microsurgery have been described to approach tumors of the oropharynx and supraglottis. Postoperative cosmesis, swallowing without aspiration, speech quality, and oncologic safety of these methods have been compared. A distinct advantage of the transcervical approaches over the transoral approach is the facility of simultaneous neck dissection.<sup>4</sup>

Within the lateral pharyngotomy approach, several alterations have been described. Laccourreye described the "extended lateral pharyngotomy" for resection of lesions of the lateral tongue base after induction chemotherapy. Four steps were described: 1) removal of the lateral wing of the hyoid bone, 2) transection of the digastric muscle, stylohyoid muscle, and ansa hypoglossi including its branches to the mylohyoid and infrahyoid muscles, 3) ligation of the first two branches of the lingual artery, and 4) transection of the lateral floor of the oral cavity.<sup>5</sup>

We performed three modifications of the traditional lateral pharyngotomy approach and labeled them Type II, Type III, and Type IV. Type I and Type II LP exposed the ipsilateral base of tongue, while Type III and IV LP exposed the entire base of tongue. Laccourreye was able to expose superior structures such as the entire mobile tongue and the soft palate, but did not mention exposure of inferior structures, such as the postcricoid area and the arytenoids. These were visible in Type II LP.

Our modifications differed from previously described approaches. We chose to include ligation of the superior laryngeal artery instead of branches of the lingual artery. We did not include removal of the lateral wing of the hyoid bone, but did transect the digastric and stylohyoid muscles. We were able to expose similar structures as Laccourreye without disrupting the hyoid bone.

The extended lateral pharyngotomy was shown useful for lateral tongue base tumors.<sup>5</sup> All tumors of this region are not amenable to transoral endoscopic excision and all centers are not trained in this skill; therefore, LP may be useful in this situation. Additionally, the transhyoid approach is useful for approaching tumors of the base of tongue, but not tumors that extend from the base of tongue to the vallecula.<sup>1</sup> LP would be more appropriate in these patients. In our study, Type IV pharyngotomy provided exposure of the vallecula in 5 of 5 cadavers.

Sacrifice of the superior laryngeal nerve is rarely needed, and results in significant functional deficits.<sup>1</sup> We did not need to sacrifice the superior laryngeal nerve in any of the cadavers to facilitate exposure.

As in all approaches, there are limitations of the LP method. Advanced supraglottic tumors requiring total laryngectomy are not appropriate for the traditional approach, or for Type II, III, or IV LP.<sup>1</sup> If complete exposure of a lesion is not possible by either transoral or transcervical approach alone, a combination may be utilized.

As in staging of head and neck malignancies, a widely accepted classification system facilitates comparison of incidence, treatment, and outcomes. We were interested in creating a classification system of LP to assist with documentation and communication. This system would also simplify the choice of extension of the traditional approach depending on the structure to be visualized.

Further modifications of lateral pharyngotomy may be added in the future. After all, the lateral pharyngotomy approach was first described over a century ago and several modifications have been described since.<sup>6,7</sup> For instance, mandibulotomy may be included as type V.

## CONCLUSIONS

A variety of modifications of the LP approach may be used for surgical excision of lesions of the oropharynx and supraglottis. A widely-accepted classification system would provide consistency in surgical documentation and comparing end results as well as in communicating about patients. Our system provides additional exposure of both cephalic and caudal structures. A subtype of LP may be chosen based on the target structures.

## REFERENCES

1. Carron R L, Soose R J. Lateral Pharyngotomy in Myers Operative Otolaryngology- Head and Neck Surgery 2008, Saunders, Philadelphia.
2. Cheever DW. Cancer of the tonsil: Removal of the tumor by external incision. (A second case.) Boston Med Surg J 99:133-139.
3. Holsinger FC, Laccourreye O, Weber RS. Surgical approaches for cancer of the oropharynx. Op Techniques in Otolaryng 2005; 16:40-48.
4. Ferris RL, Myers EN. Suprahyoid pharyngotomy. Op Tech Otolaryngol 2005;16:49-54.
5. Laccourreye O, Seccia V, Ménard M, et al. Extended Lateral Pharyngotomy for Selected Squamous Cell Carcinomas of the Lateral Tongue Base. Annals of Otology, Rhinology & Laryngology 118(6): 428-434.
6. Stem SJ. Anatomy of the lateral pharyngotomy approach. Head Neck 1992;14:153-6.
7. Orton HB. Lateral transthyroid pharyngotomy: Trotter's operation for malignant conditions of the laryngopharynx. Arch Otolaryng 1930; 52:321-338.