

# Burning Mouth Syndrome: A rare manifestation of Lyme disease.

Kaelan Young, BS<sup>1</sup>; Timothy DeKlotz, MD<sup>2</sup>; Michael Reilly, MD<sup>2</sup>;

<sup>1</sup>Georgetown University School of Medicine, Washington, DC

<sup>2</sup>Department of Otolaryngology-Head & Neck Surgery, Georgetown University Hospital, Washington, DC;



## Introduction

Burning mouth syndrome (BMS) is a poorly understood process hallmarked by a severe burning sensation of the oral or oropharyngeal mucosa. It is estimated to afflict up to 1.3 million people in the United States alone<sup>1</sup>. BMS has been theorized to be caused by a multitude of factors, but to the authors' knowledge, this is the first report of Lyme disease as a possible etiology. As the fund of knowledge regarding Lyme disease has grown, the often variable presentation of its many manifestations requires the treating physician to possess a high degree suspicion to accurately diagnosis and treat these patients.

## Cases

### Case 1

A 58-year-old woman presented to the Otolaryngology clinic with a primary complaint of a burning sensation at the tip of her tongue. Symptoms started simultaneously with her diagnosis of Lyme disease (six months prior to presentation). Since her initial diagnosis, she has been treated with two courses of doxycycline with resolution of her fatigue but with no effect on her glossodynia. She also complains of an alteration in her taste and now has a sensation of all foods being salty. The remainder of her past medical history was non-contributory. The review of symptoms was otherwise negative.

Physical exam revealed no visible or palpable lesions in the areas reported to be causing pain. The remainder of the head and neck exam was within normal limits. Laboratory evaluation revealed only a mild vitamin B12 deficiency while chemistries, rheumatologic panel, and the remainder of the vitamin panel were all within normal limits. She has been treated with vitamin supplementation, another cycle of high dose doxycycline (after consultation with infectious disease), and a trial of systemic steroids without any symptomatic improvement.

### Case 2

A 69-year-old female presented to the Otolaryngology clinic with a chief complaint that her "mouth is on fire". The patient reports symptoms for the past 10 years that began coincident with her diagnosis of Lyme disease. The severe burning sensation is focused in her oropharynx. She reports waxing and waning symptoms over this period with temporary relief following several treatment cycles of doxycycline. Associated with her complaint is an alteration in taste with an inability to appreciate sweet foods. Her medical history is significant for gastroesophageal reflux but has no extra-esophageal symptoms. She is currently being treated with a proton pump inhibitor.

Physical exam revealed normal appearing mucosa with no visible or palpable lesions of the oral cavity or oropharynx. The remainder of the head and neck exam was all within expected limits with the exception of some mild inter-arytenoid edema and erythema found on flexible laryngoscopy. Laboratory studies revealed a mild iron and vitamin D deficiency. Comprehensive metabolic panel, complete blood count, endocrine, rheumatologic and the remainder of the vitamin panel studies were all within normal limits. The patient was started on vitamin D supplementation and treatment with an additional three-week course of doxycycline, although has failed to demonstrate symptomatic improvement.

## Discussion

Burning mouth syndrome (BMS) is classically an idiopathic condition that presents as a pain or burning of the oral and/or oropharyngeal mucosa without any identifiable lesions or systemic causes for the disease. Associated symptoms include xerostomia and dysgeusia, although mono- and oligo-symptomatic forms lacking these features exist and are more common than the classic triad above<sup>2</sup>. Symptoms typically present in middle age with a significant female predominance. The definitive pathophysiology behind this disease is largely unknown. Theorized causes include peripheral nerve injury, nutritional deficiencies (notably vitamin B12 as well as other B-complex vitamins), and psychosomatic factors<sup>1</sup>.

Lyme disease is a tick born disorder that is caused by the bacteria *Borrelia burgdorferi*, a gram-negative spirochete<sup>3</sup>. It is characterized by the classic skin rash, erythema migrans, but can also cause a variety of symptoms such as neurological, cardiac, and joint disorders. A variety of head and neck manifestations have been reported and include (but are not limited to) lymphadenopathy, facial paralysis, facial pain, vocal cord paralysis, TMJ disorders, facial spasms, facial paresthesias, dysphagia, hearing loss, and changes in vision<sup>4</sup>.

Neurological symptoms can be found in up to fifteen percent of patients with Lyme disease<sup>5</sup>. Cranial neuropathies are a common presentation of infection<sup>6</sup> with the findings dictated by the specific nerves involved, but most commonly a facial nerve palsy. Appropriate treatment will often improve the symptoms, but an incomplete response is not uncommon. These neurological deficits are thought to occur secondary to direct neural invasion by the spirochetes with the subsequent inflammatory reaction mediating injury<sup>7</sup>. While it is not known whether the nutritional deficiencies identified in the described cases were secondary to lyme infection, they may have contributed to their oral pain. Vitamin B12 deficiency, as noted previously, has been found in association with BMS<sup>1</sup>.

Neurological insult by *B. burgdorferi* to the mandibular division of the trigeminal nerve or to the glossopharyngeal nerve are possible pathophysiologic explanations in these two patients with a painful burning sensation of their anterior tongue and oropharynx. The associated dysgeusia can be explained by injury to the chorda tympani nerve supplying taste to the anterior two thirds of the tongue, or the glossopharyngeal nerve supplying the posterior two thirds. While a direct cause-and-effect relationship can not be unquestionably established, the temporal relationship between the diagnosis of Lyme disease and the onset BMS yields strong support to this diagnosis in the two cases presented. The chronicity and unsatisfactory treatment options available, as evidenced by these two patients, make this disease process a troublesome entity to manage.

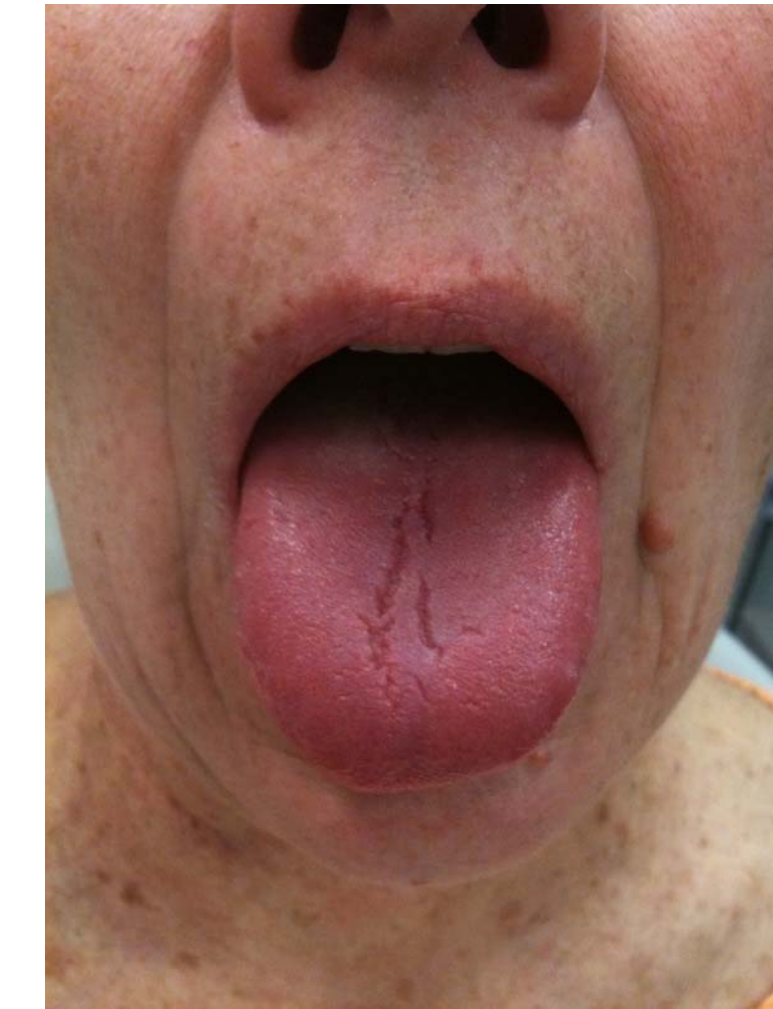


Fig. 1. Photograph of patient 1 demonstrating no obvious lesions of the tongue. Physical exam revealed no palpable abnormalities as well.

## Conclusions

BMS is a poorly understood pain syndrome that is characterized as oral mucosal pain, dysgeusia, and xerostomia with a lack of physical findings. Oligo-symptomatic forms of the disease exist in which dysgeusia and xerostomia contribute to varying degrees. The pathophysiology of this disorder is largely unknown although peripheral nerve injury and vitamin/mineral deficiency are postulated to be potential etiologies. Lyme disease has many potential head and neck presentations although a review of the literature reveals that this is the first report of BMS as a potential manifestation.

## References

1. Scala, A. C. (2003). Update on burning mouth syndrome: overview and patient management. *Crit Rev Oral Biol Med*, 14, 275-291.
2. Zakrzewska J., F. H. (2009). Interventions for the treatment of burning mouth syndrome (Review). *The Cochrane Collaboration*, 1-22.
3. Franz, J. K. (2003). Lyme disease (Lyme borreliosis). *Best Practice & Research Clinical Rheumatology*, 17 (2), 241-264.
4. Rubel, J. (2006). Lyme disease symptoms and characteristics: a compilation of peer-reviewed literature reports. *Lyme info*. Retrieved (2010, September 12) from <http://www.lymeinfo.net/medical/LDSymptoms.pdf>
- Malawista, S. B. (2007). Lyme Disease. In L. A. Goldman, *Cecil Medicine* (23rd ed., p. Ch. 342). Philadelphia, PA: Saunders Elsevier.
- Halperin, J. (1998). Nervous system Lyme disease. *Journal of Neurological Sciences*, 153, 182-191.
- Pachner, A. S. (2007). Lyme neuroborreliosis: infection, immunity, and inflammation. *Lancet Neurol*, 6, 544-552.