



# Endoscopic Resection of Pre-Pontine Epidermoid Cysts

Yoav Hahn, MD<sup>1</sup>; Joshua Krass, DO<sup>2</sup>; Seilesh Babu, MD<sup>1</sup>; Daniel Pieper, MD<sup>2</sup>; Eric Sargent, MD<sup>1</sup>  
<sup>1</sup>Michigan Ear Institute <sup>2</sup>Michigan Head & Spine Institute

## ABSTRACT

**Objective:** To describe an innovative endoscopic technique to treat pre-pontine epidermoid cysts.

**Study design:** Retrospective study at tertiary referral center.

**Methods:** Two patients with a rare cyst in the pre-pontine region are presented. These cysts are typically resected in a microsurgical fashion and can be associated with significant risks and complications. This study is the first description of a solely endoscopic removal of epidermoid cysts and evaluates the operative findings and postoperative course. Intra- and post-operative complications, post-operative imaging, resolution of symptoms, and technique is assessed.

**Results:** Both patients had complete resection of the epidermoid cyst using a completely endoscopic technique. Patients were discharged from the hospital on post-operative day 1 and 2. No intraoperative or postoperative complications occurred. Post-operative imaging revealed no edema of the cerebellum and complete resolution of the cyst.

**Conclusions:** Endoscopic resection of midline pre-pontine epidermoid cysts can be accomplished with less retraction of the brain and with improved visualization of the pathologic process.

## CONTACT

Yoav Hahn, M.D.  
Michigan Ear Institute  
yhahn00@yahoo.com  
248-865-4135

## INTRODUCTION

Over the last several years there has been a shift from open, microscopic procedures to minimally invasive techniques to lessen the operative morbidity and improve outcomes for various skull base procedures. Open endoscopically-assisted procedures have been developed to lessen some of the complications associated with skull base surgery, however the drawback to these techniques remains the reliance on retraction and/or resection of vital structures to adequately visualize the surrounding basal cisterns and brainstem. Utilizing an endoscope as the sole means to access the CPA and pre-pontine space allows excellent visualization of the pathology with no need for retraction.

We report our experience treating pre-pontine epidermoid cysts utilizing a completely endoscopic technique.

## METHODS AND MATERIALS

Two patients, 55 and 62 years old respectively, each presented with a history of headaches and cranial nerve deficits. In each patient, magnetic resonance imaging showed a large T1 hypointense/T2 hyperintense mass occupying the posterior suprasellar, premesencephalic, and prepontine cisterns, with significant mass effect on the brainstem. Presumed on the basis of imaging characteristics to have epidermoid cysts, both patients underwent a retrosigmoid approach using a 14 mm craniectomy. Dural opening is made at the transverse and sigmoid sinus junction. A 4mm, 0° endoscope is cannulated along the posterior aspect of the petrous bone following the ventral aspect of the cerebellum. A 30° endoscope was also utilized.

## RESULTS

Both patients had total resection of the epidermoid cyst using a completely endoscopic technique. Patients were discharged from the hospital on post-operative day 1 and 2, respectively. No intraoperative complications occurred. Post-operative imaging revealed no edema of cerebellum and resolution of the cyst.

Patient 1 was found to have a postoperative aseptic meningitis, which was adequately treated with steroids. Patient 2 had no postoperative complications. Both patients have been followed for over a year and are doing well. Their preoperative symptoms including headaches and cranial nerve deficits have resolved

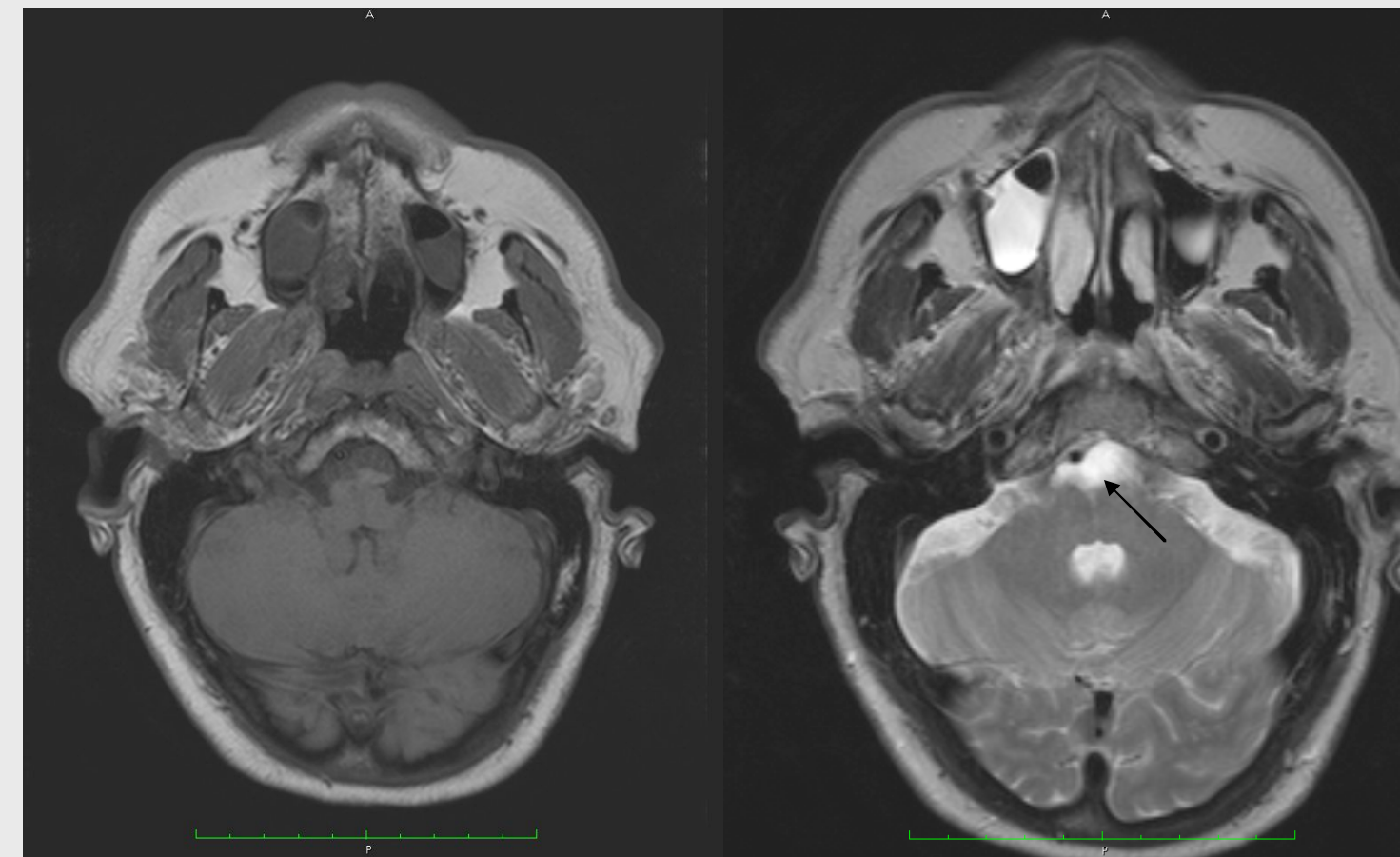


Figure 1. Preoperative T1 and T2 MRI imaging showing epidermoid cyst and compression of midbrain structures (arrow)

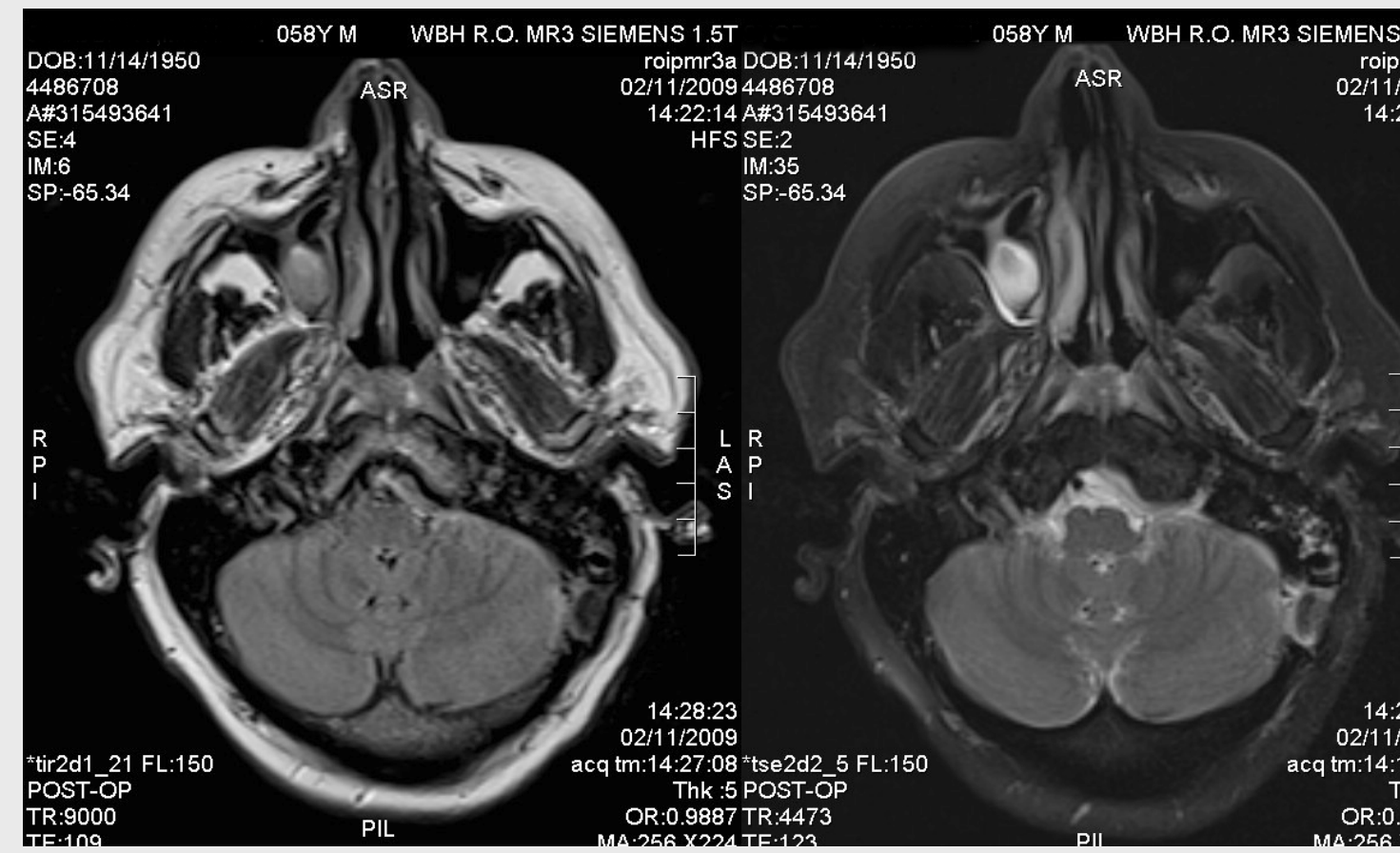


Figure 2. Postoperative T1 and T2 MRI imaging showing complete resection of epidermoid cyst (arrow)

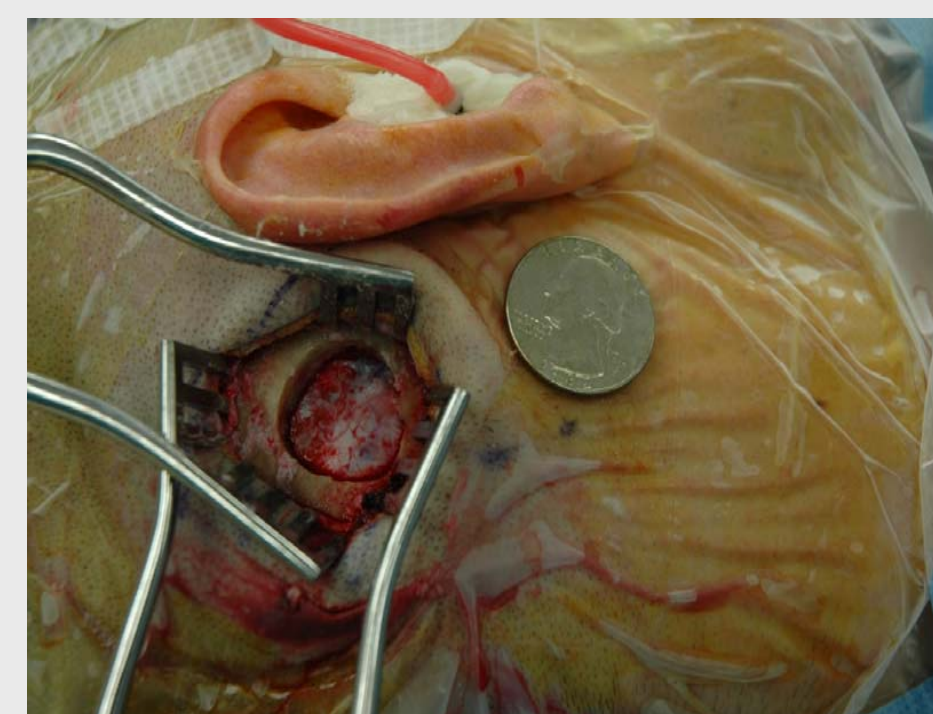

Figure 5. 14 mm craniectomy

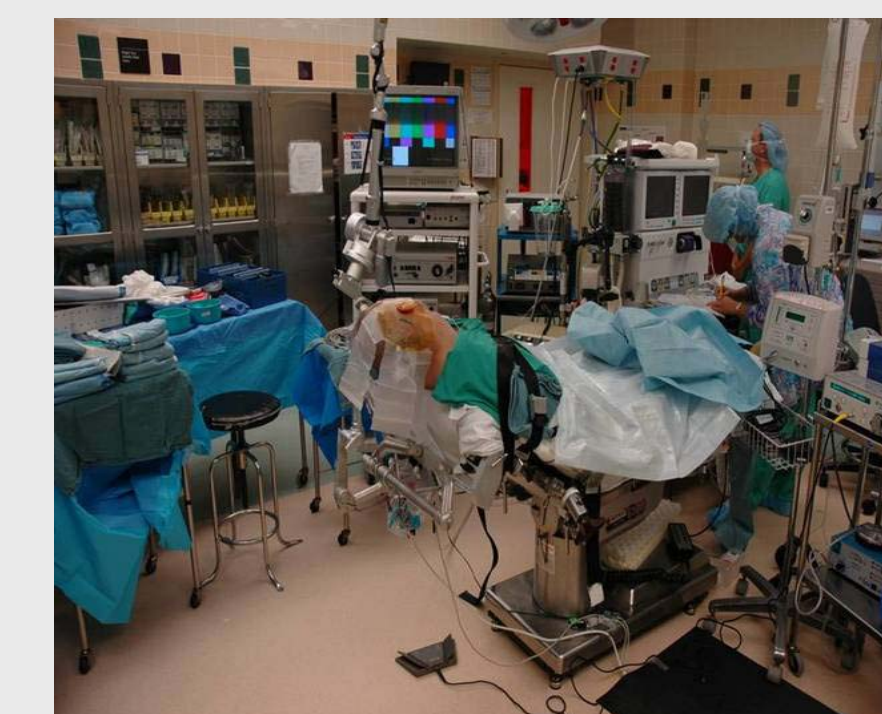

Figure 6. OR setup

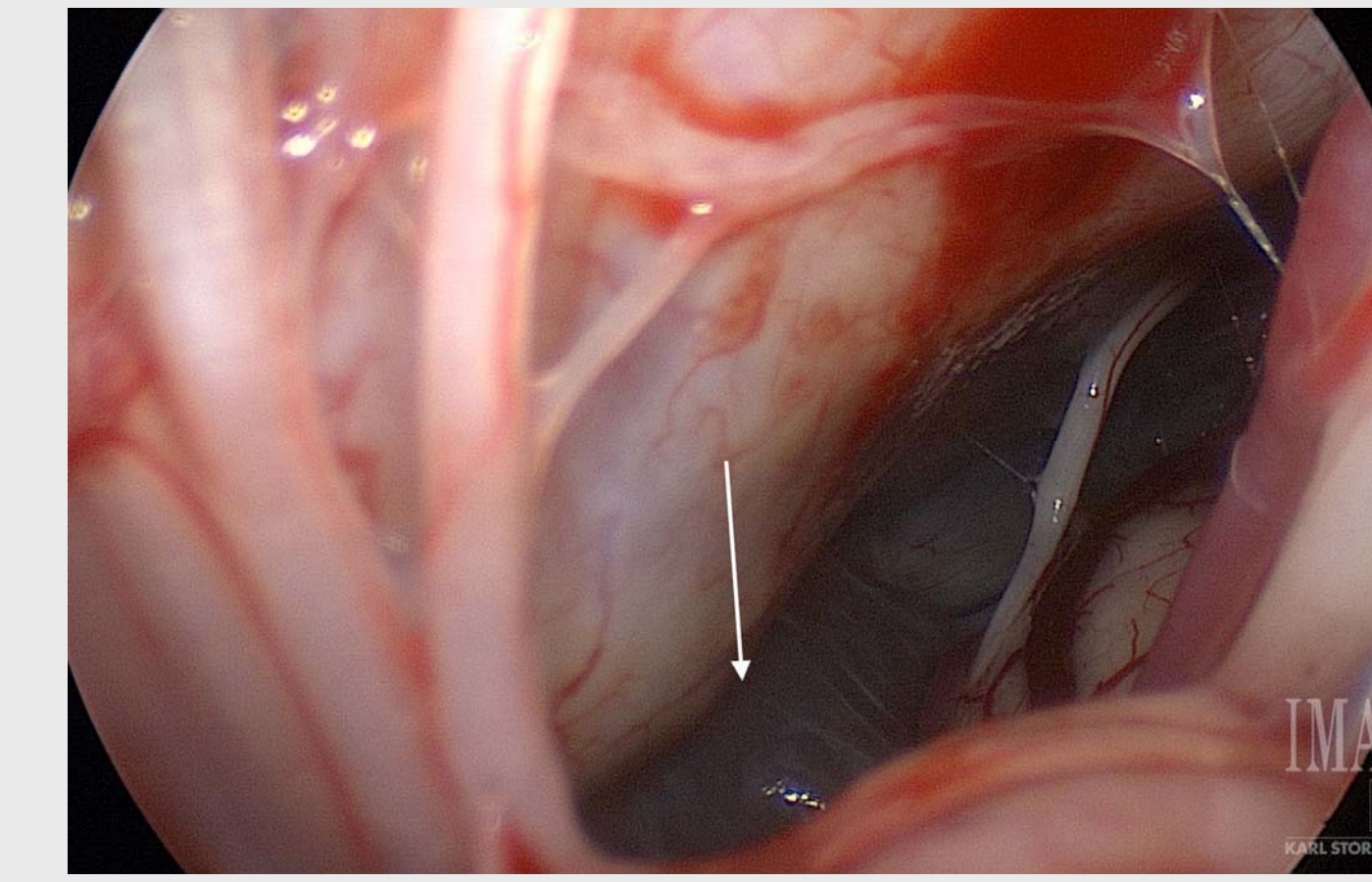


Figure 3. Large epidermoid cyst (arrow). Note CN 9-11 inferiorly and CN 7-8 superiorly.

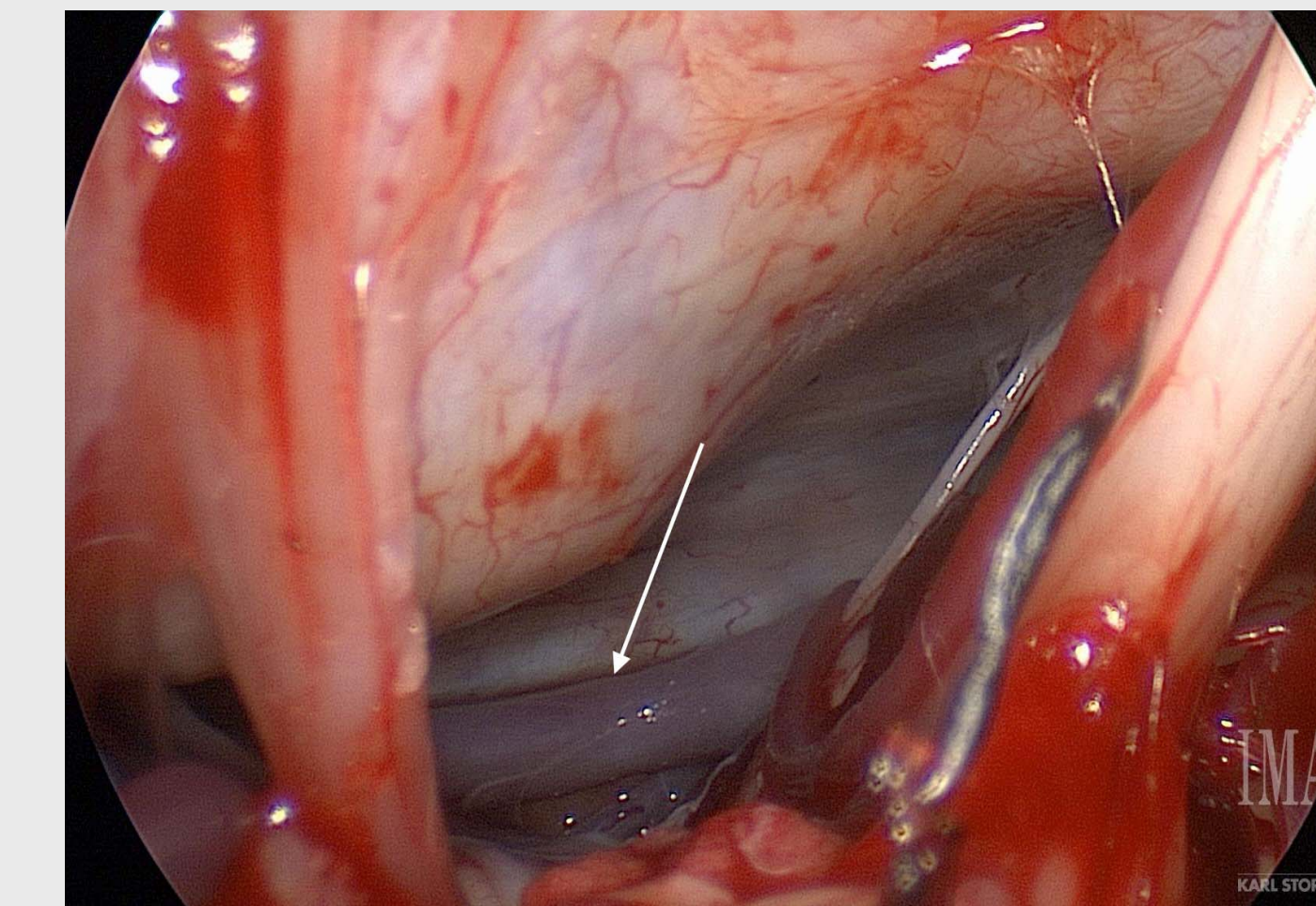


Figure 4. After resection of cyst cavity. Arrow points toward basilar artery.

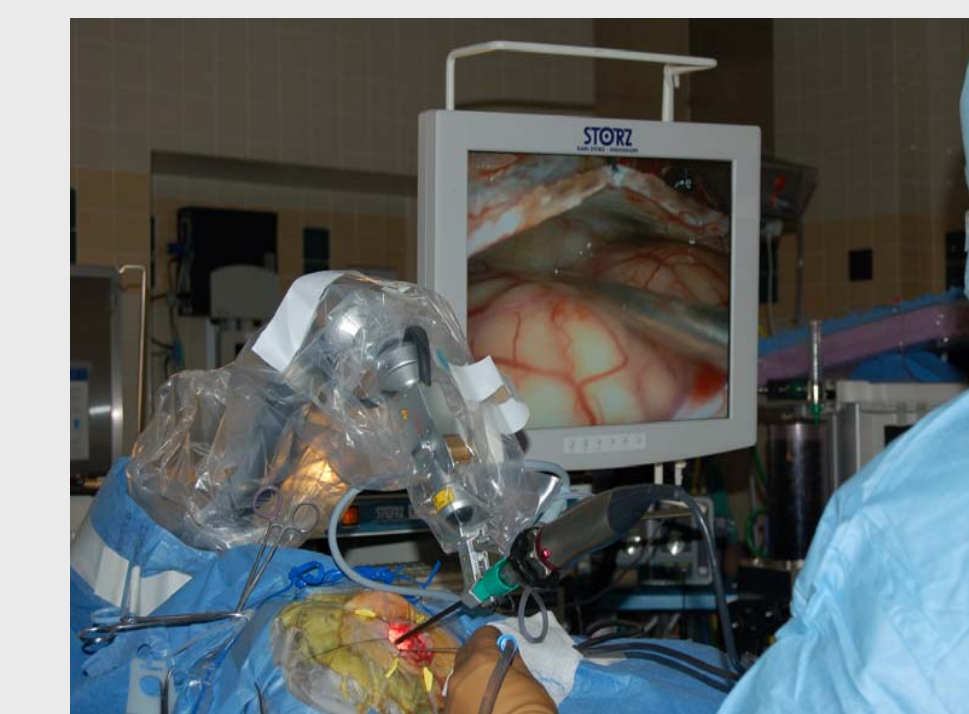

Figure 7. Hydraulic Mitaka arm

## DISCUSSION

Standard skull base procedures typically combine drilling of and around complex structures, resection/transection of venous sinuses, sacrifice of hearing, and resection of brain tissue. With these standard techniques there is increased risk of cerebrospinal fluid leakage, infection, brain contusion or infarction, and cranial nerve damage. When the endoscope is used as the sole means of accessing lesions in the posterolateral skull base and midline pre-pontine space, a much smaller craniectomy is used and the need to resect or retract brain tissue is obviated, thereby decreasing the post-operative morbidity typically associated with treating pathology located in this delicate region.

Despite the inherent advantages of a purely endoscopic approach there are specific limitations. Radiographic evidence of increased intracranial pressure or mass effect surrounding the cerebellum causing absence of the interpeduncular and/or prepontine cisterns is considered a contraindication to this approach and should be dealt with through a more open approach.

## CONCLUSIONS

By using the endoscope to gain access to the posterolateral skull base surgeons can achieve enhanced visualization of the CPA, posterior fossa contents, pre-pontine cisterns, and various pathology that may be encountered in this region. In addition, there is also a minimal craniectomy involved and no need for retraction of the cerebellum, thereby limiting post-operative morbidity. Secondary to these benefits we feel that the endoscopic approach to midline lesions is an invaluable technique to treat a wide array of pathology found in this region, including but not limited to epidermoid cysts as shown in this review.

## REFERENCES

- Andrews RJ, Bringas JR: A review of brain retraction and recommendations for minimizing intraoperative brain injury. *Neurosurgery* 33(6): 1052-1064, 1993.
- Fujimoto S, Kuyama H, Nishimoto K, Akioka T, Nagao S: Effect of local retraction on local cerebral blood flow and neural function. *Neurol Med Chir* 22:893-900, 1982.
- Heros RC: Brain resection for exposure of deep extracerebral paraventricular lesions (technical note). *Surg Neurol* 34:188-195, 1990.
- Fries G, Perneczky A: Endoscope-assisted brain surgery: Part 2-Analysis of 380 procedures. *Neurosurgery* 42:226-232, 1998.
- Shevach I, Cohen M, Rappaport ZH: Patient positioning for the operative approach to midline intracerebral lesions: Technical note. *Neurosurgery* 31:154-155, 1992.
- Day JD, Kellogg JX, Tschabitscher M, Fukushima T: Surface and superficial surgical anatomy of the posterolateral cranial base: Significance for surgical planning and approach. *Neurosurgery* 38(6): 1079-1084, 1996.
- Rhoton, Albert Jr., M.D.: Surface and superficial surgical anatomy of the posterolateral cranial base: Significance for surgical planning and approach. *Neurosurgery* 38:1083-1084, 1996 (comment).